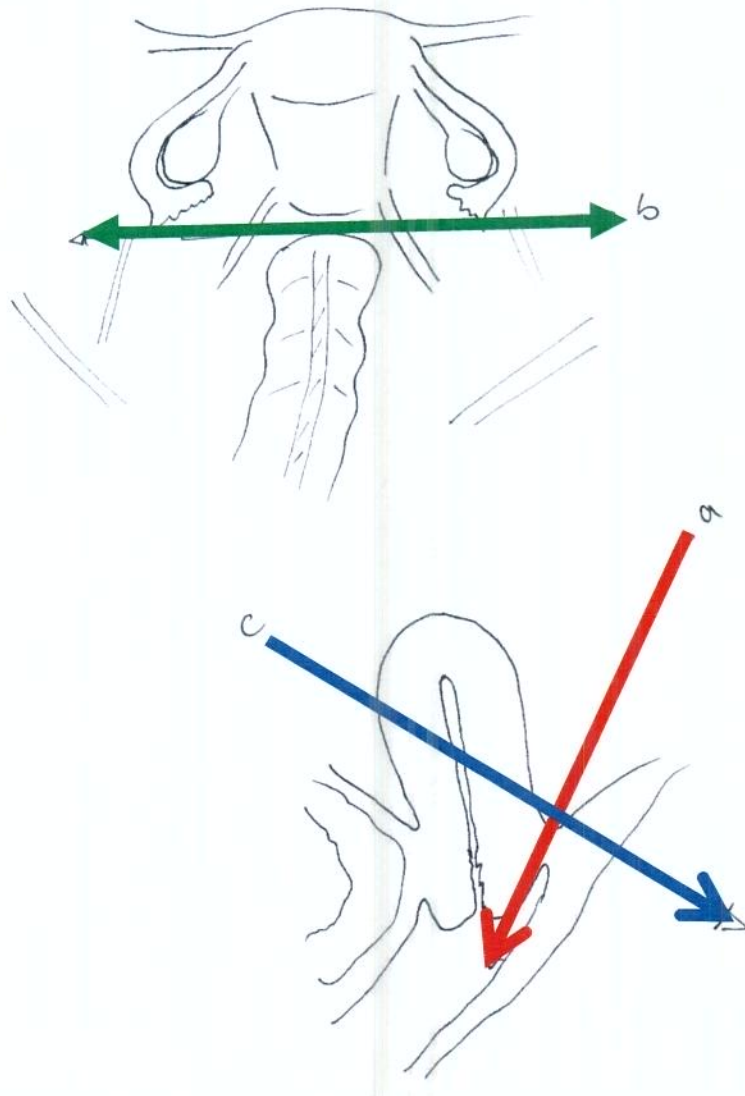


EZIAN Score

copyright F.Tuttliès 2/2010



3 Raumachsen

- A Douglas – Septum rectovaginale - Scheide
- B Ligg sacrouterina - Beckenwand
- C Organüberschreitung zum Rektum

- Ergänzungen
 - » Blase
 - » Darm
 - » Ureter
 - » Andere (Diaphragma,..)

rev ENZIAN


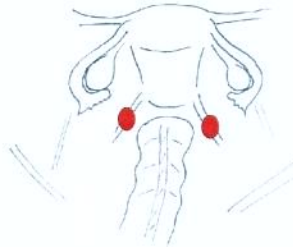




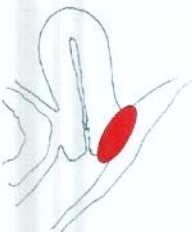
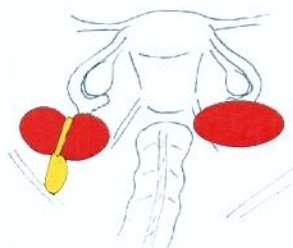

2/2010 ©Tuttlies

Stadium	A Septum rectovaginale Scheide	B Ligg sacrot Beckenwand	C Rektuminfiltration
1	< 1 cm	< 1 cm	< 1 cm
2	1 – 3 cm	1 – 3 cm	1 – 3 cm
3	> 3 cm	> 3 cm	> 3 cm

rev ENZIAN 2/2010 ©Tuttlies

Stadium	A Septum rectovaginale Scheide	B Ligg sacrou Beckenwand	C Rektuminfiltration
1	< 1 cm	< 1 cm	< 1 cm
2	1 – 3 cm	1 – 3 cm	1 – 3 cm
3	> 3 cm	> 3 cm	> 3 cm

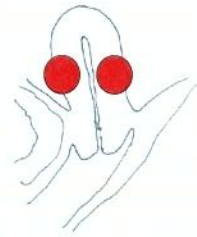rev ENZIAN 2/2010 ©Tuttlies

Raum- achse Stadium	A Septum rectovaginale Scheide	B Ligg. Sacrouterinae Beckenwand	C Rektum/Sigma
1 <1cm	 <p>RevE1A < 1 cm</p>	 <p>RevE1B < 1 cm</p>	 <p>RevE1C < 1 cm</p>
2 1-3 cm	 <p>RevE2A 1-3 cm</p>	 <p>RevE2B 1-3 cm</p>	 <p>RevE2C 1-3 cm</p>
3 >3cm	 <p>RevE3A >3 cm</p>	 <p>RevE3B >3 cm</p>	 <p>RevE3C >3 cm</p>

Extragenitale Erweiterung

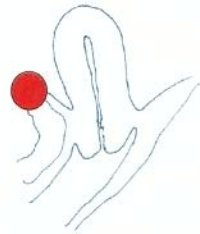FA

Adenomyose Uterus



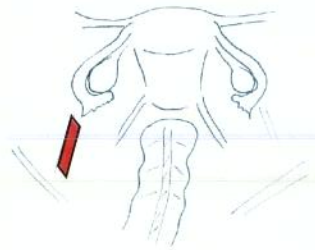
FB

Blase



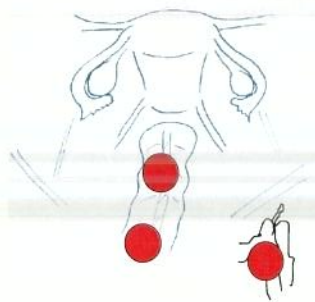
FU

Ureter instrinsisch



FI

Intestinum
Sigma, Coecum,
term. Ileum



FO

andere Lokalisationen
Diaphragma,....

